# HD-bekæmpelsesprogram

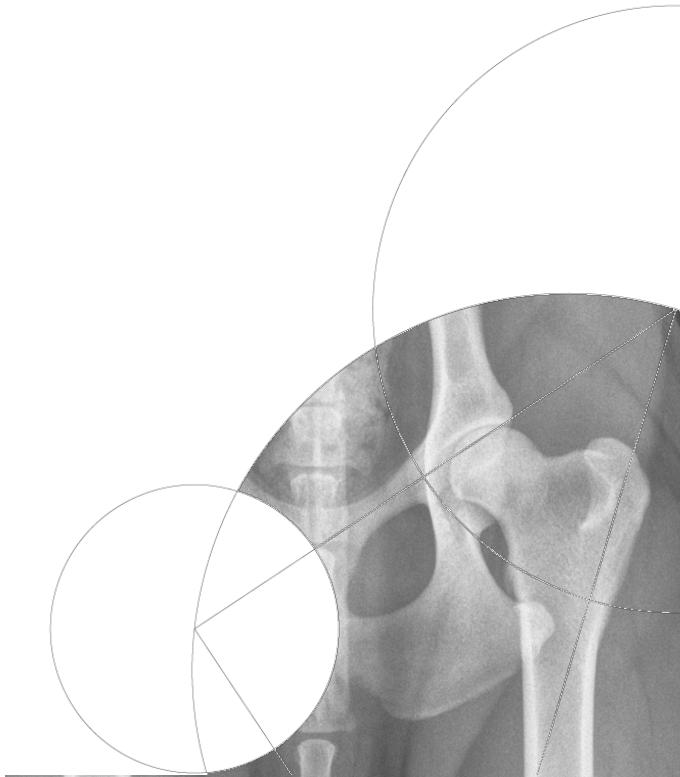

# 1937

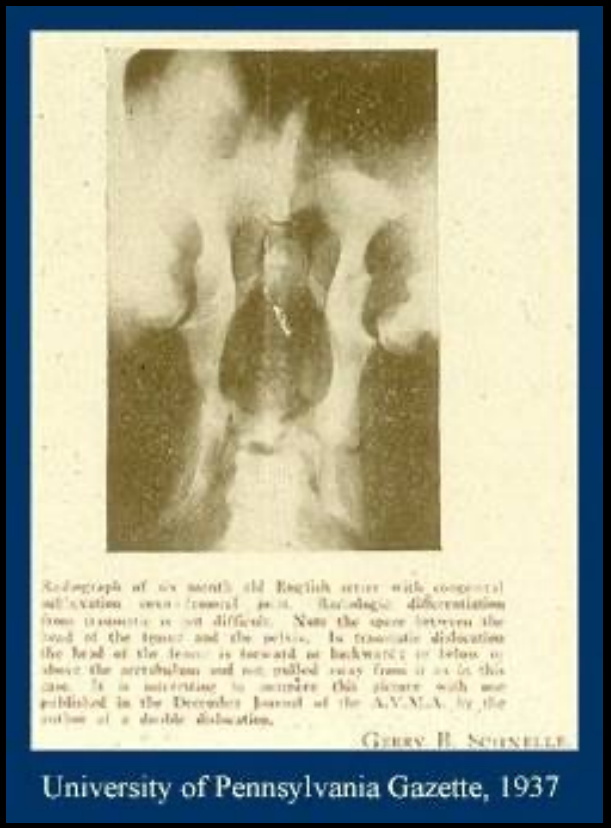

University of Pennsylvania Gazette, 1937

”The condition described herein, rare though it may be, should be recognized as being congenital and potentially hereditary, and the dog or bitch in which it occurs should be destroyed or sterilized in the eugenic interest of the breed”

# Hofteledsdysplasi

Multifaktoriel

- Arv
  Polygenetisk
- Miljøpåvirkning
  Væksthastighed, fodring, motion

# Hip Dysplasia

”a varying degree of laxity of the hip joint permitting subluxation during early life, giving rise to varying degrees of malformation of the femoral head and acetabulum and finally inevitably leading to osteoartritis” (1966)

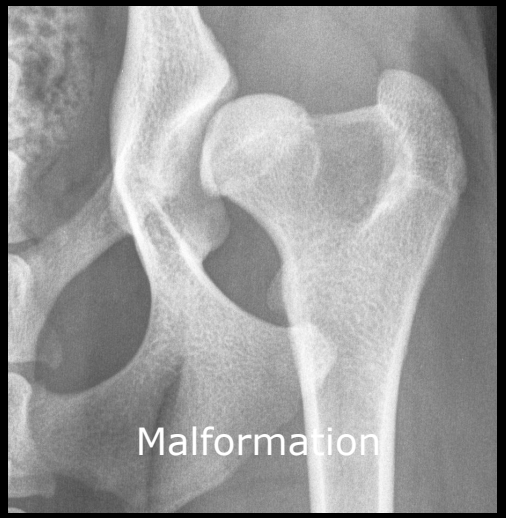

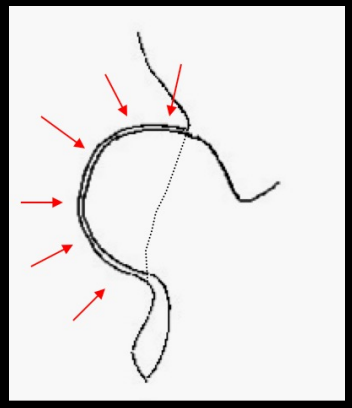

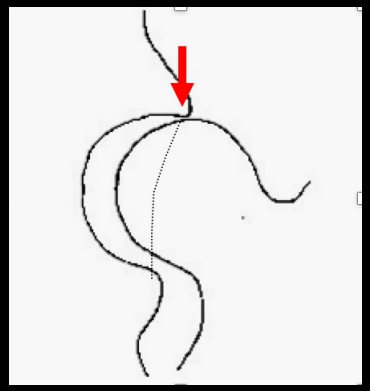



# Udvikling over tid

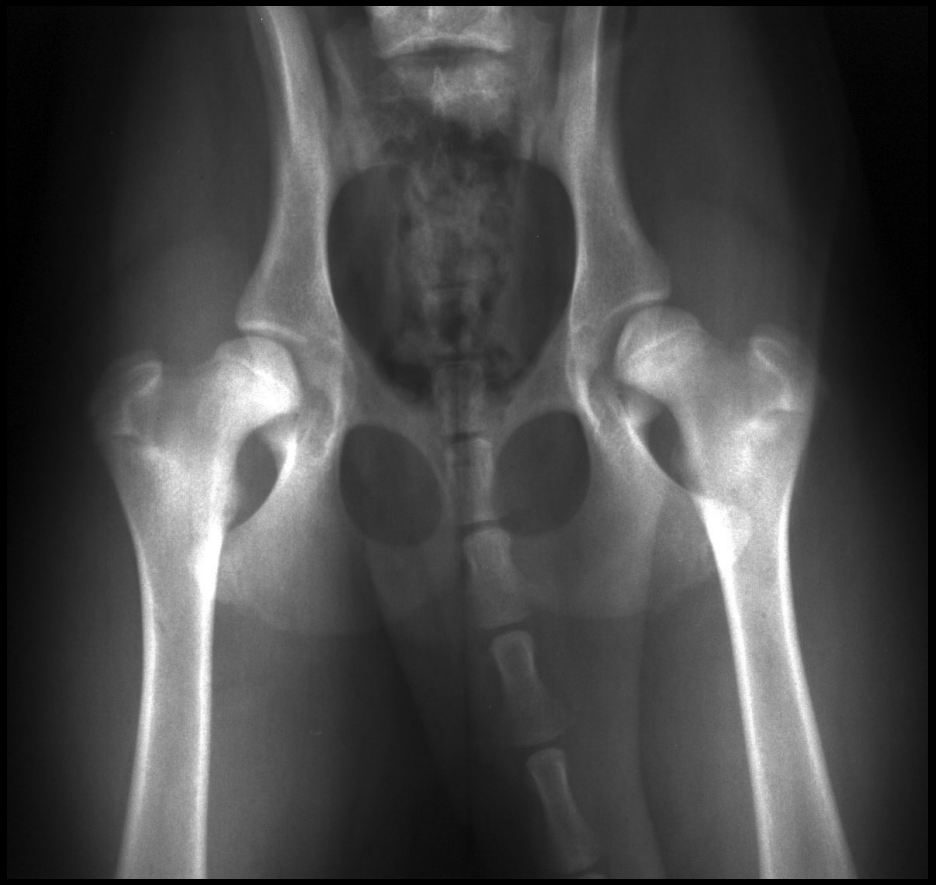

7 months

9 months

Udredning

# Udvikling over tid

1 år 3 mdr

2 år 6 mdr

Screening

# Forskellig målsætning

Forskel på hunden med kliniske symptomer og hunden der kommer for at blive røntgenundersøgt i forbindelse med et bekæmpelsesprogram

Den halte hund
- Udredning
- Den enkelte hund
- Ofte flere projektioner
- Klinikeren bestemmer

Bekæmpelsesprogram
- Udvælgelse af avlsdyr
- Racen
- Fastsatte projektioner mm.
  - HD (FCI)

# Udredning

Oversigt

# Udvælgelse af avlsdyr

Billedkvalitet

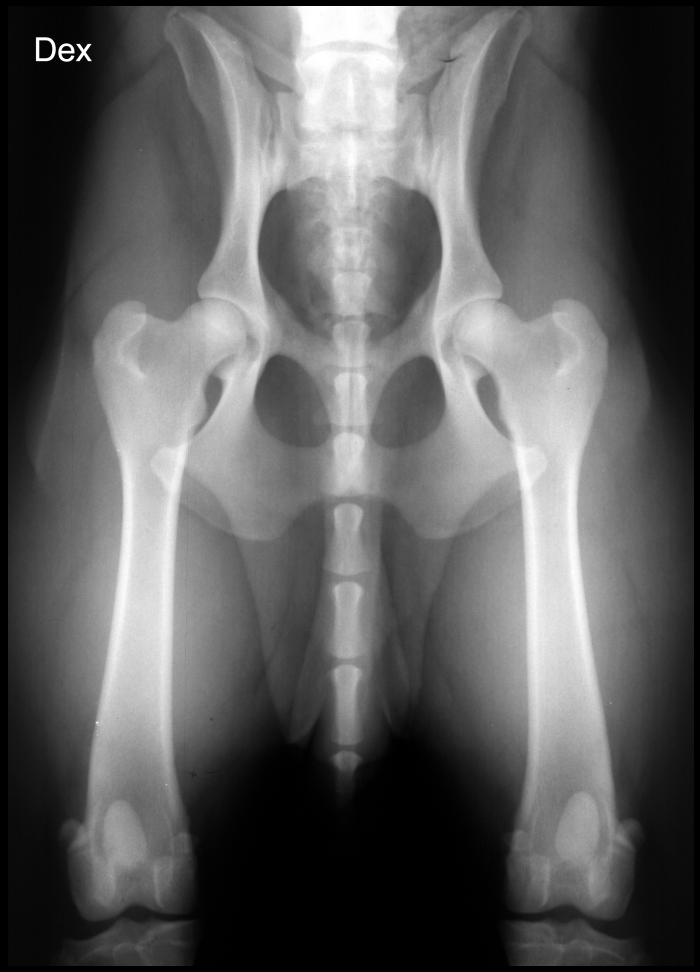


Positionering

# Diagnostisk sensitivitet

- 25% ved 6 måneder
- 70% ved 12 måneder
- 95% ved 24 måneder

(Schæferhund)

# For-fotografering

7 mdr.

12 mdr.

# HD-procedure

FCI protokollen (Copenhagen 2022)
(Féderation Cynologique International)

Forudsætninger for bedømmelse
Teknisk kvalitet
Evaluering/klassificering

# Forudsætninger for bedømmelse
# administrative krav

Hundens alder

Identitet
Permanent mærkning af røntgenoptagelserne
Ejers underskrift
Dyrlæges underskrift
Sedering
Omfotografering

Korrekt udfyldt rekvisition

# Permanent mærkning af røntgenoptagelserne

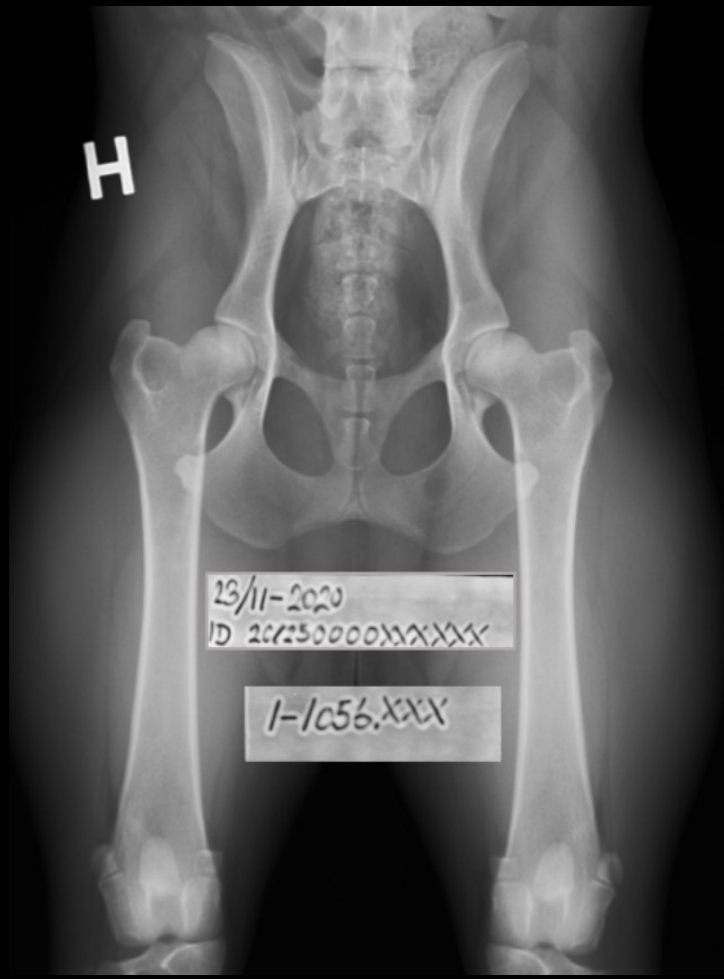

# Forudsætninger for bedømmelse
## krav til billedkvalitet

- Radiografisk kvalitet
- Positionering

The radiographs quality has to be such as to allow accurate visualization of the anatomy of the hip joint.

Important: the dorsal edge of the acetabulum must be clearly visible through the femoral head

# Den dorsale acetabularrand

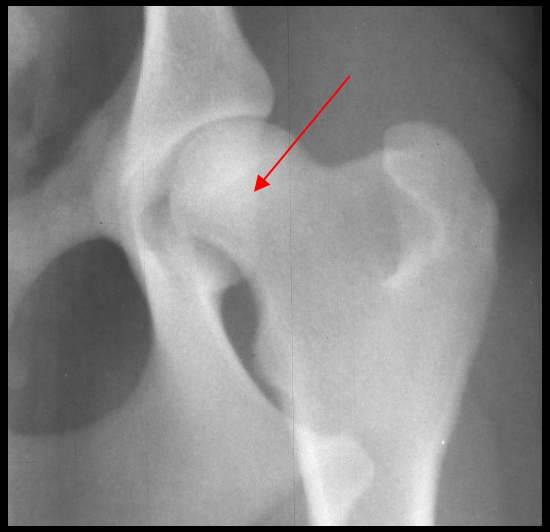

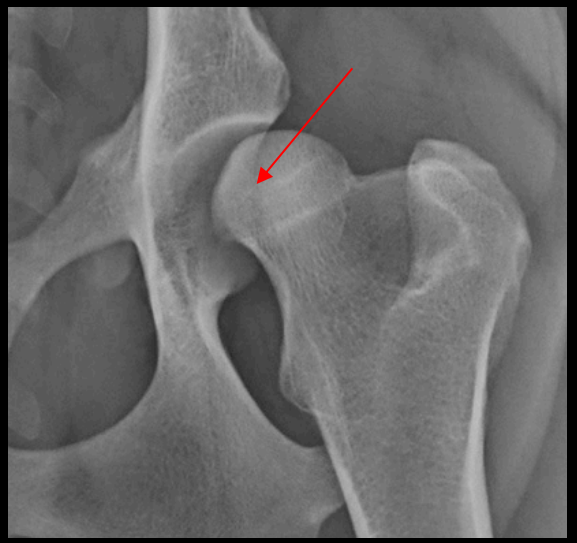

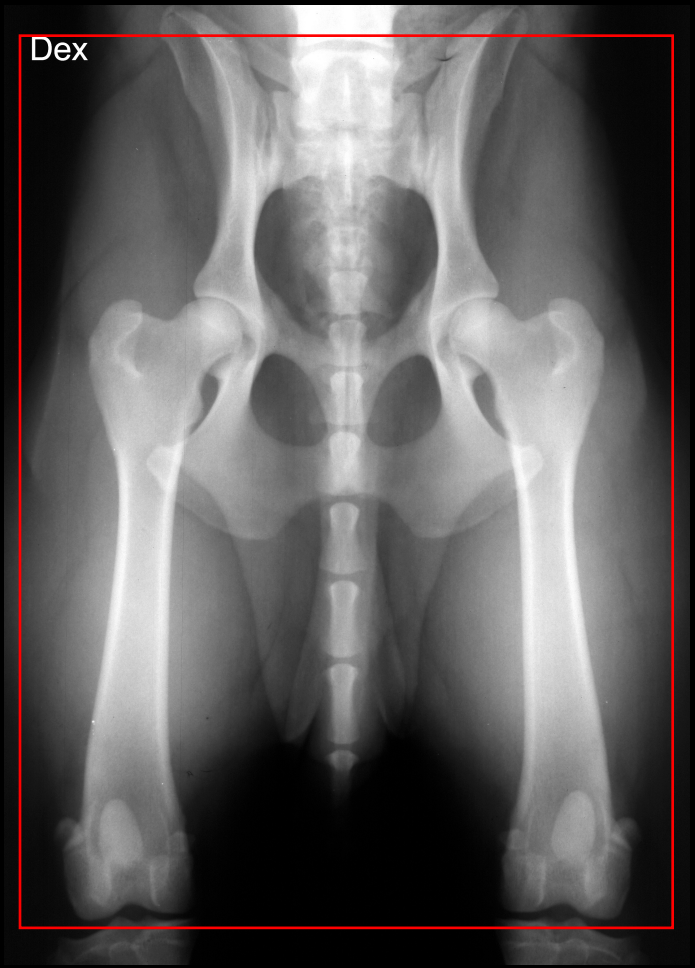


The minimum size of the radiographic image must be such as to include the pelvis up to a level of os sacrum and both patellae

The beam is centered at the caudal end of the pelvis, which can be palpated. The beam is collimated to ensure complete visualisation of the pelvis and the patellae

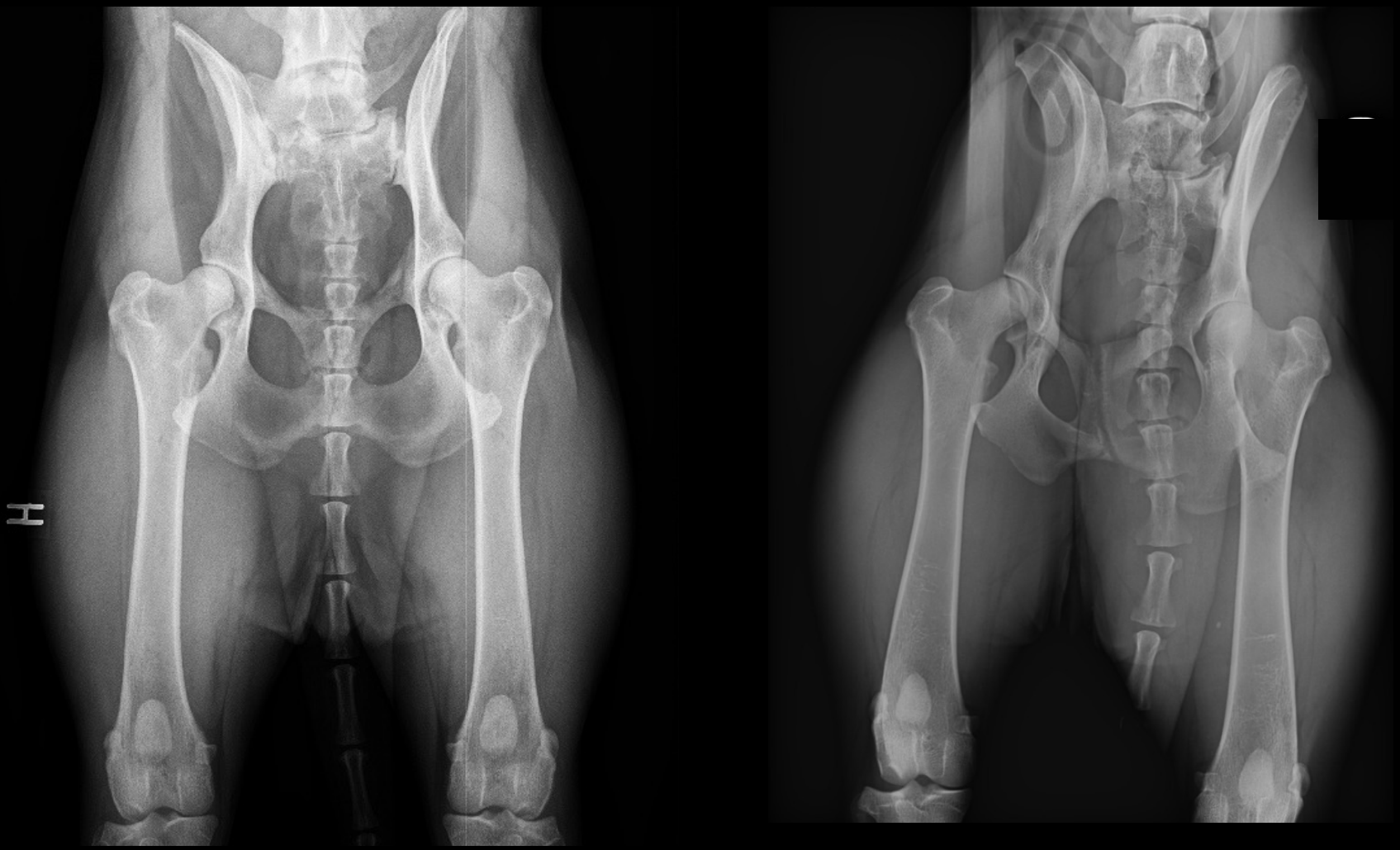

Transitionel vertebrae

H
V

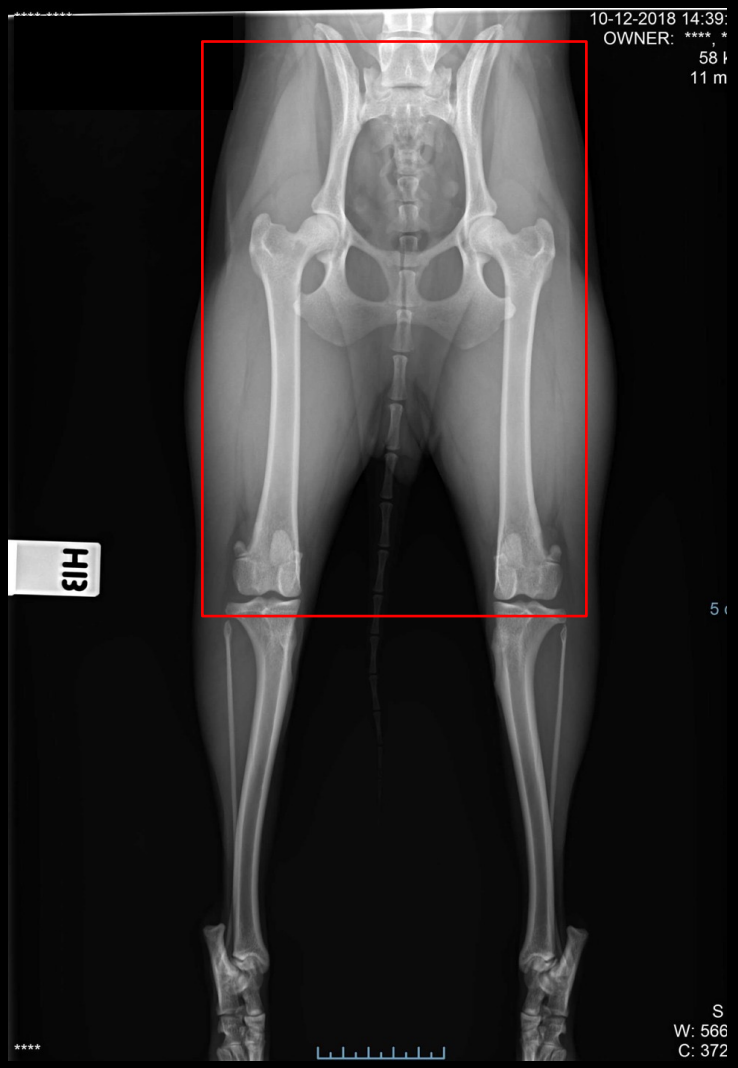
10-12-2018 14:39:
OWNER: **** , *
58 k
11 m
H13
5 (
S
W: 566
C: 372
****

The dog must be placed with the spine in close contact to the surface of the table

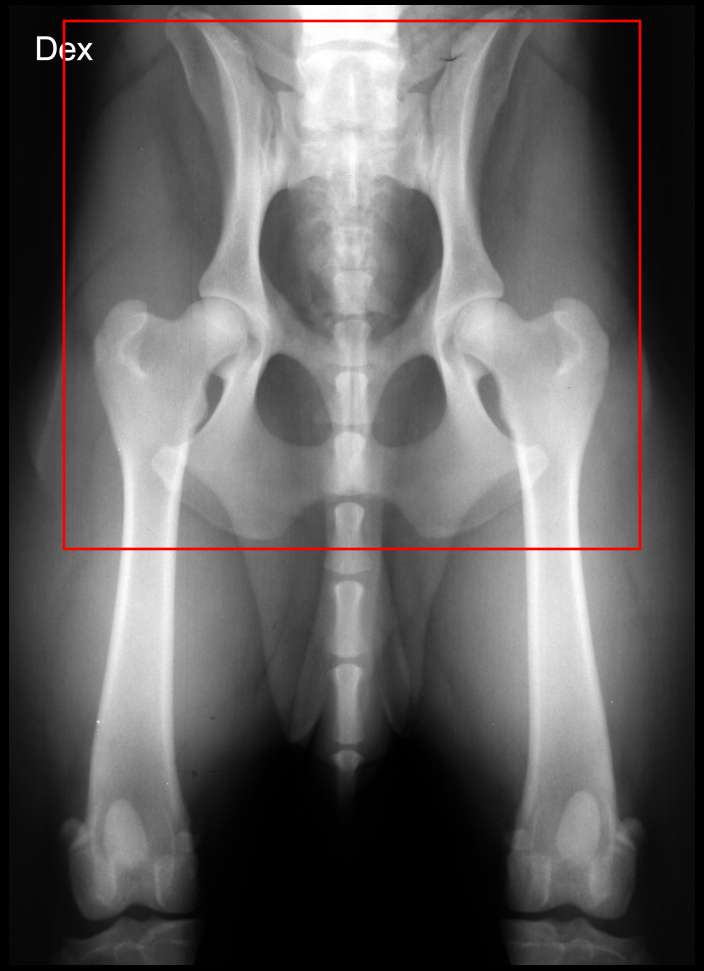


The positioning of the dog must ensure that the pelvis is symmetrical and not tilted to any side

# Pelvic rotation to the left over the long axis

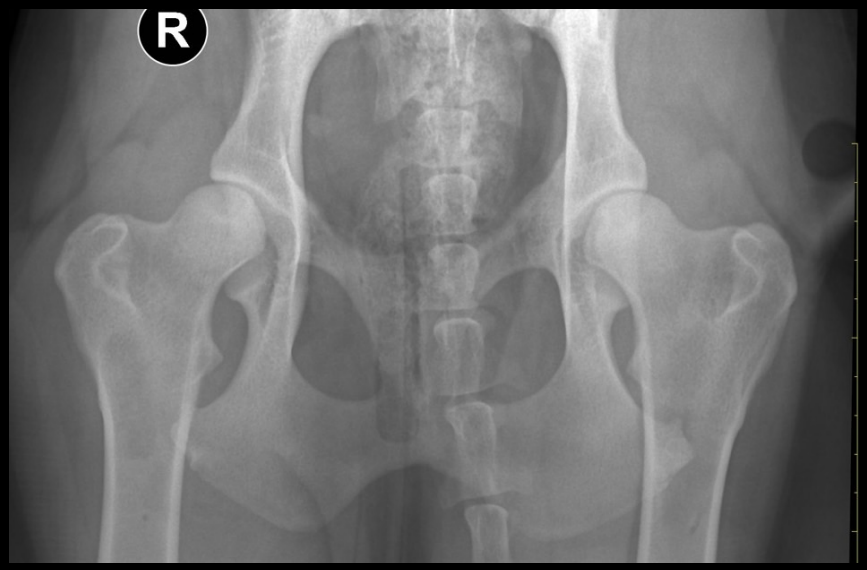

Pelvic rotation to the left over the long axis

# Pelvic rotation over the short axis

# Pelvic rotation over the short axis

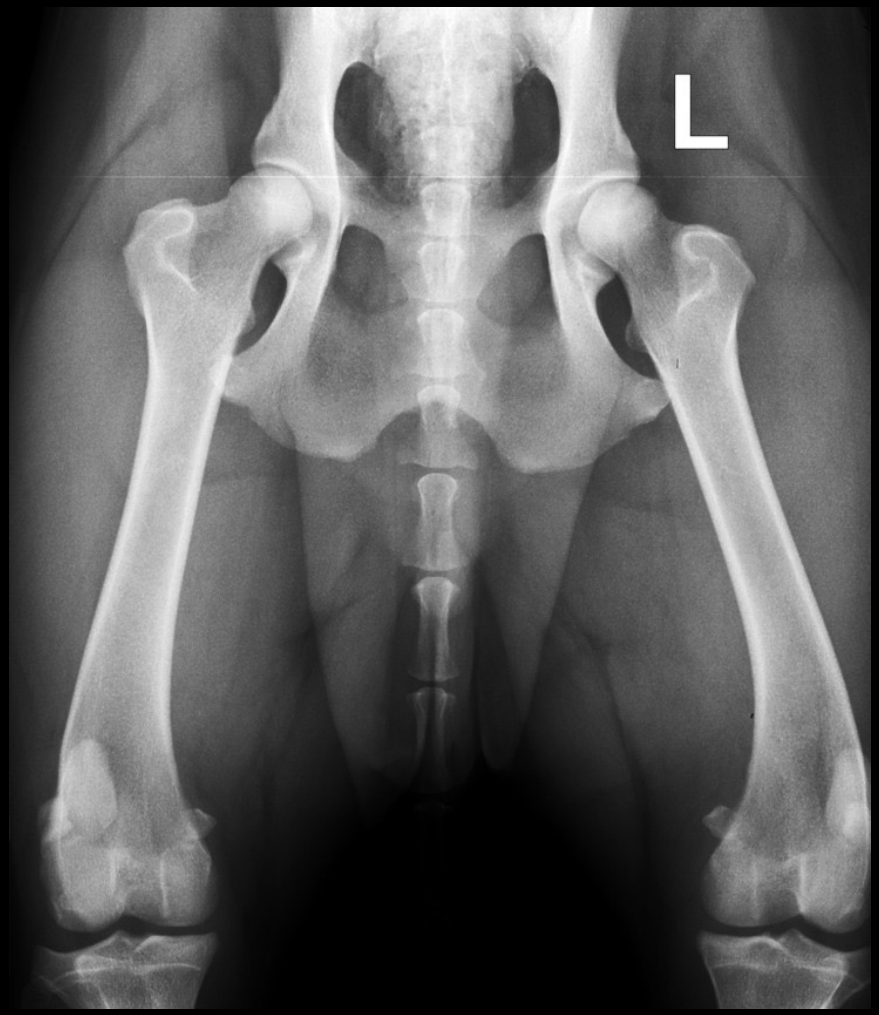

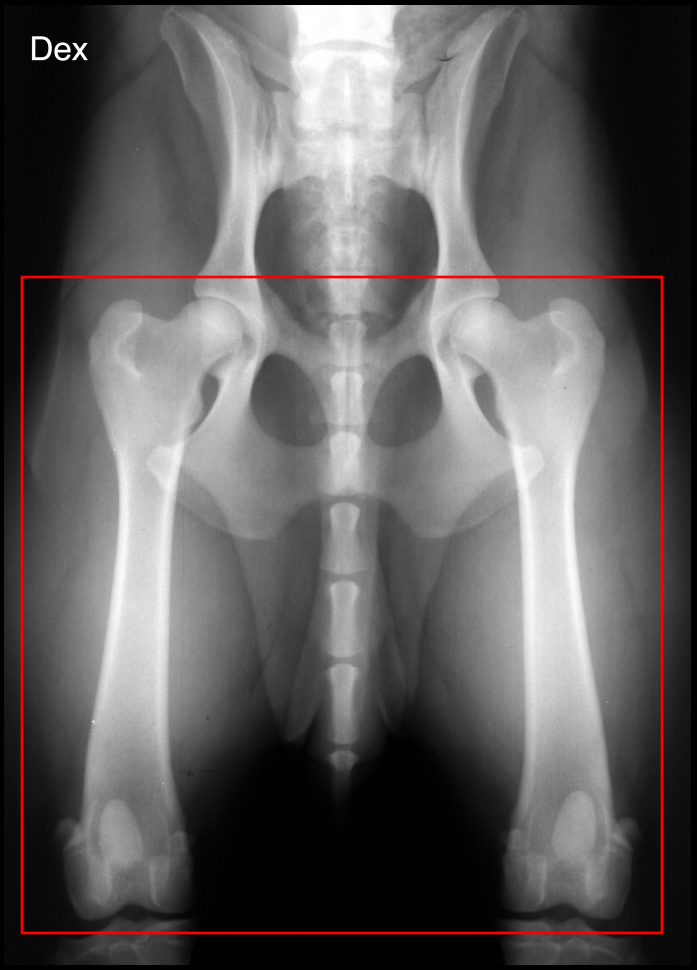


Both ossa femoris must be parallel to each other and to the sagital plane

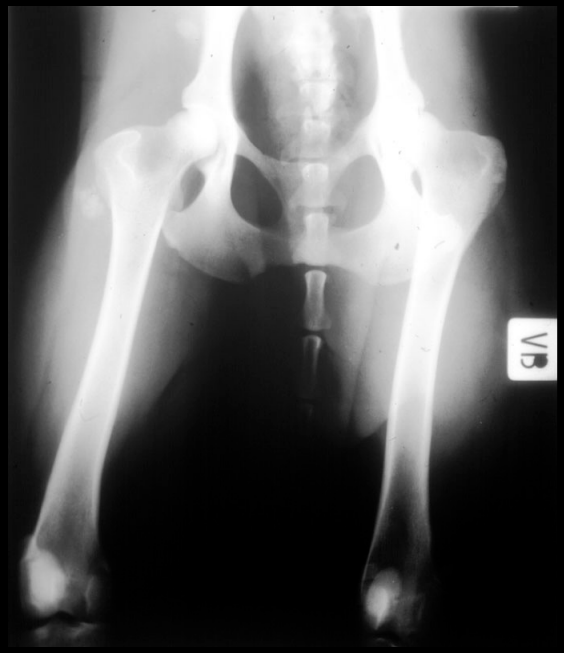

Both ossa femoris must be <u>parallel</u> to each other and to the sagital plane

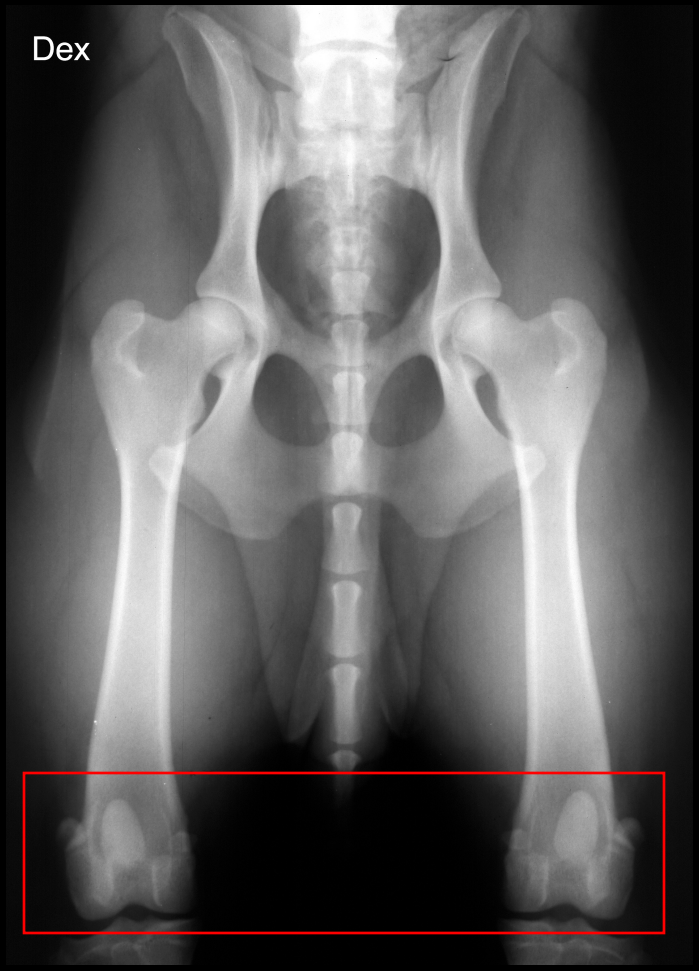


The knees must be pronated so that the patellae are projected in sulcus intercondylaris on femur

The knees must be pronated so that the patellae are projected in sulcus intercondylaris on femur

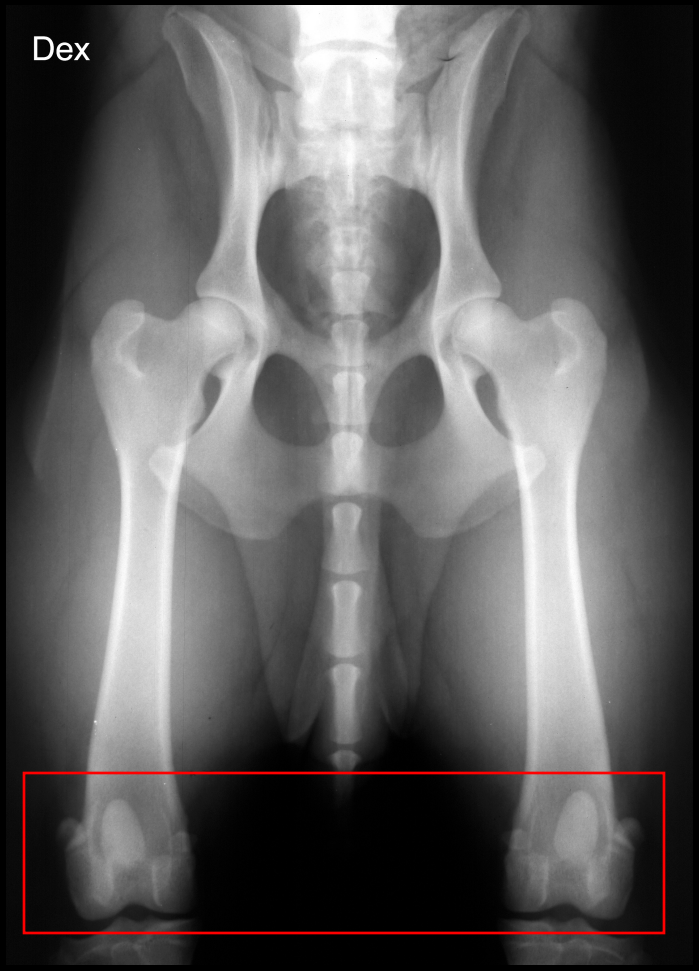


The knees must be held in a position close to the table

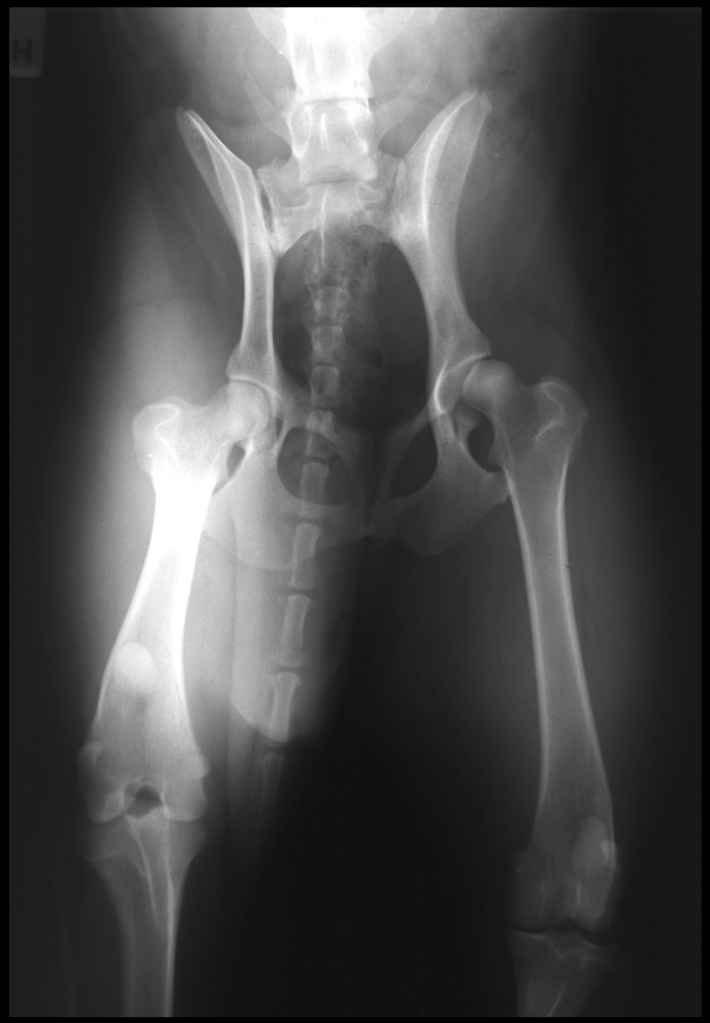

The knees must be held in a position close to the table

# Sedering/anæstesi Hunden skal være tilstrækkelig afslappet

Angivelse af hundens vægt

Anvendte præparater og dosis:

- Butorphanol
- Dexmedetomidin

im.

Evt.:

- Fentanyl
- Propofol

iv og evt. intubering.

# Positionering

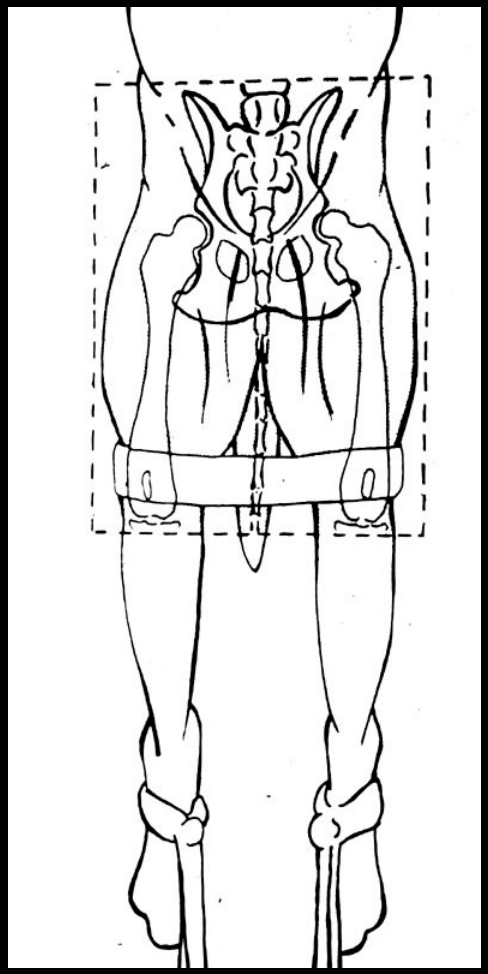

# Positionering (korrekt)

# Positionering (ukorrekt)

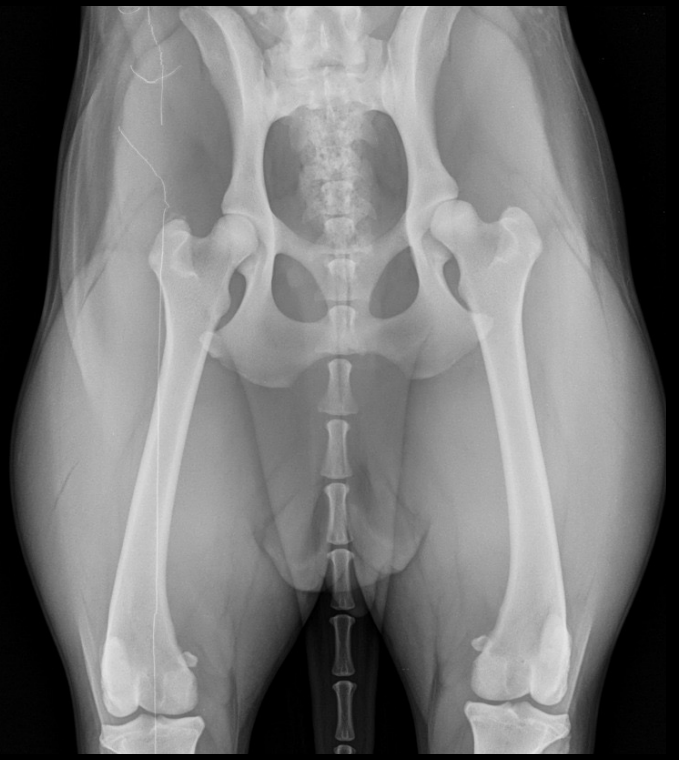

Dansk Kennel Klub
Medlem af Fédération Cynologique Internationale (FCI)
Parkvej 1, 2680 Solrød Strand

**Rekvisition HD-bedømmelse**

Dato:
Sagsnr.:

**Oplysninger om hunden / Dog**
Race / Breed: Køn / Sex:
DKK reg.nr. / Reg. No.: Farve / Colour: Født / Date of birth: ID-nummer / Chip and/or Tattoo
Navn / Registered Name:

**Oplysninger om dyrlæge / Veterinarian**
Telefonnr. / Phone
Aut.nummer:
Optagedato: Ved anden dato end anførte, udfyld i hånden Dato:
Ved brug af anden dyrlæge end ovenfor anførte, udfyld i hånden - Dyrlæge: Aut.nummer:
Adresse: Postnr. og by

**Udfyldes af dyrlæge**
Billeder er fremsendt som: Sedation/narkose:
☐ CD Præparat: Navn(e):
☐ Alm. røntgen Dosis:
☐ Upload Hundens vægt: kg
VB anbefaler, at dyrlægen ikke udtaler sig til ejer om mulig status. Har dyrlægen til trods herfor givet ejeren en vurdering? Ja ☐ Nej ☐
Har hunden tidligere vært bedømt? Ja ☐ Nej ☐

**Dyrlæges underskrift og stempel**
Dato / date Underskrift og stempel / Veterinarian's signature and stamp
*Ovennævnte dyrlæge bekræfter med sin underskrift, at identiteten for ovenstående hund er kontrolleret ved aflæsning af ID-nummer på hunden. Ovenstående dyrlæge bekræfter samtidig med sin underskrift at der hermed bekendt, ikke er foretaget operativt indgreb for HD/AD/OCD.*
*With his/her signature the above veterinary surgeon confirms that the identity of the above dog has been controlled by reading the dog's ID number. At the same time, the above veterinary surgeon confirms with his/her signature that he/she is not aware of any surgical interventions for HD (hip dysplasia), ED (elbow dysplasia) or OCD (osteochondritis dissecans) performed on the dog in question.*

**Ejers underskrift**
Dato Underskrift
*Resultatet af sundhedsundersøgelsen skal indsendes til DKK. Resultatet offentliggøres på www.hundeweb.dk og DKK kan videregive resultatet til brug i avlsrelateret arbejde eller i statistisk og videnskabeligt øjemed. HD/AD/OCD billeder er DKK's ejendom.*
*The result of the health examination must be sent to the DKK. The result is published at www.hundeweb.dk and the DKK is allowed to reveal the result for purposes related to breeding, statistics or science. HD/AD/OCD pictures are the DKK's property*

**KLIP - til brug ved indfotografering**
Sagsnr.: ID-nummer Optagedato:

OBS!! Husk at rekvisition og billeder skal sendes til
Veterinær Billeddiagnostik • Universitetshospitalet for Familiedyr • IMHS • ATT: HD/AD/OCD • Dyrlægevej 32 • 1870 Frederiksberg C

+

Billeder/CD sendes til:
Veterinær Billeddiagnostik
Universitetshospitalet for Familiedyr
Att: HD/AD/OCD
Dyrlægevej 32
1870 Frederiksberg C

**ELEKTRONISK UPLOAD AF HD/AD/OCD BILLEDER**

Pr 1. januar bliver det muligt at uploade digitale HD/AD og OCD røntgen direkte til KU sund.

Kontakt KU sund for link og password på hd-kons@sund.ku.dk

# Evaluering/klassificering

FCI´s internationale 5-delte skala (Copenhagen 2022)

Klassificeringen er foretaget udelukkende på grundlag af de radiologiske fund og så objektivt som muligt

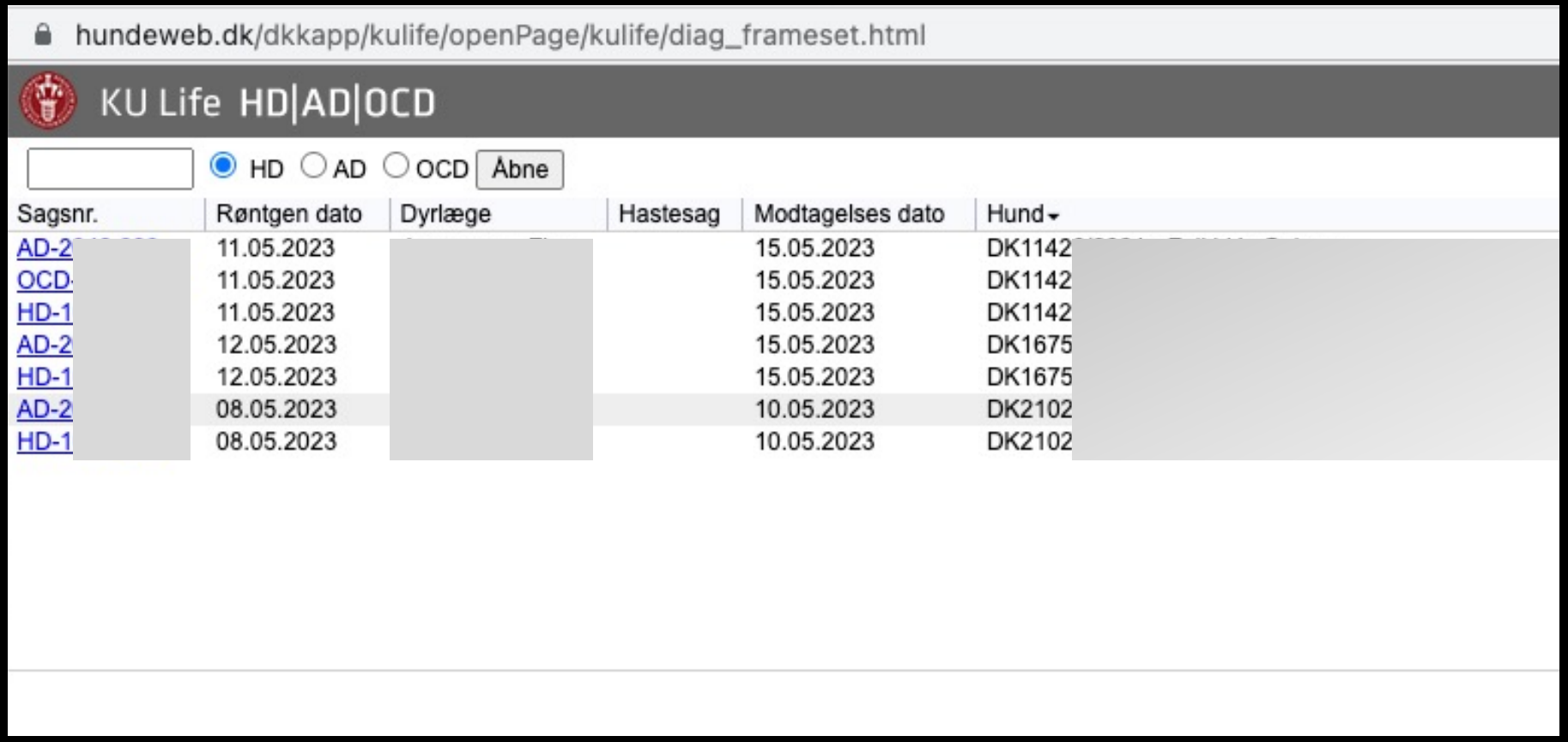
hundeweb.dk/dkkapp/kulife/openPage/kulife/diag_frameset.html
KU Life HD|AD|OCD
HD AD OCD Åbne
Sagsnr. Røntgen dato Dyrlæge Hastesag Modtagelses dato Hund
AD-2 11.05.2023 15.05.2023 DK1142
OCD- 11.05.2023 15.05.2023 DK1142
HD-1 11.05.2023 15.05.2023 DK1142
AD-2 12.05.2023 15.05.2023 DK1675
HD-1 12.05.2023 15.05.2023 DK1675
AD-2 08.05.2023 10.05.2023 DK2102
HD-1 08.05.2023 10.05.2023 DK2102

**HD SAG**

Sagsnummer
Race
Køn
Alder ved optagedato

Der findes ingen tidligere sager

Bedømmer : Vælg bedømmer

**Diagnosering**

| Diagnose højre | Diagnose venstre | Kvalitet | Positionering |
|---|---|---|---|
| ◯ A<br>◯ B<br>◯ C<br>◯ D<br>◯ E | ◯ A<br>◯ B<br>◯ C<br>◯ D<br>◯ E | ◯ 1<br>◯ 2<br>◯ 3 | ◯ 1<br>◯ 2<br>◯ 3 |
| Samlet bedømmelse: | | | |

Gem | Færdigbedømt

**HD-optagelsen kan ikke bedømmes på grund af:**

| Ukorrekt positionering | Dårlig billedkvalitet |
|---|---|
| ☐ Bækkenet er asymmetrisk | ☐ Optagelsen er overeksponert |
| ☐ Bagbenene er ikke parallelle | ☐ Optagelsen er undereksponert |
| ☐ Knæleddene er ikke pronerede | ☐ Optagelsen er uskarp/sløret |
| ☐ Knæleddene er eleverede | ☐ Fejl/uheld ved fremkaldelse |
| ☐ Se bemærkning | |
| Bemærkning til dyrlæge: | |

Gem | Returner billeder til dyrlæge

# Kvalitetskontrol

- Billedkvalitet
- Positionering
  - 1 = god
  - 2 = rimelig
  - 3 = dårlig (men acceptabel)

På Dyrlægeportalen har du mulighed for at følge med i kvaliteten af de røntgenbilleder, du indsender til bedømmelse på KU/SUND.

# Billedkvalitet

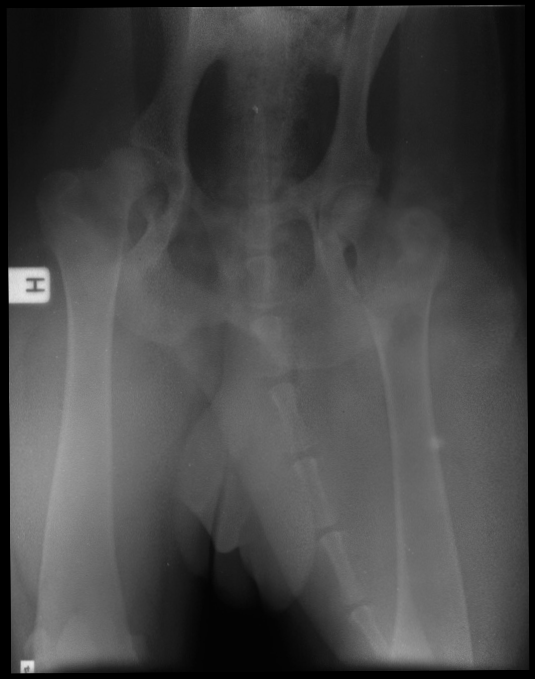

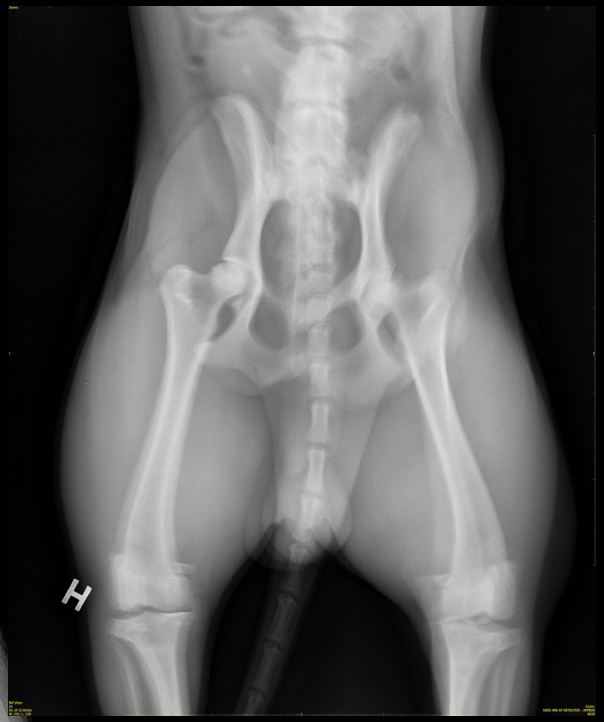

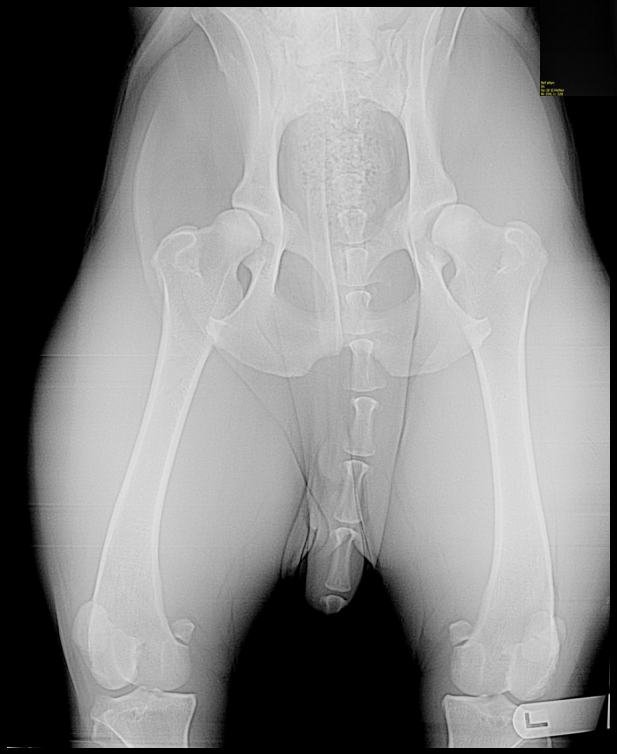

# Positionering

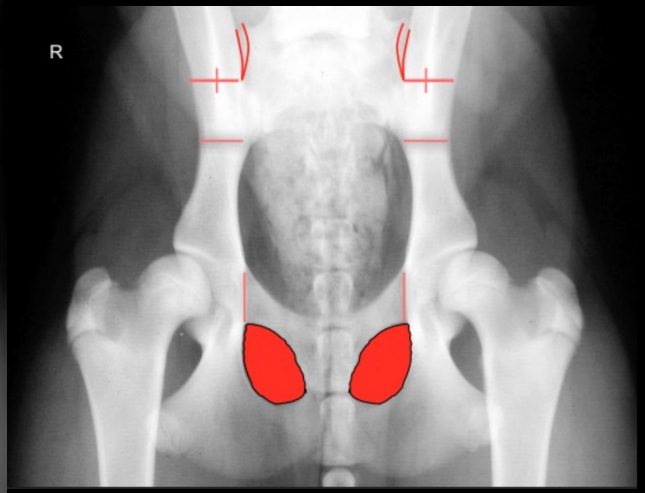

# Evaluering

Ledslaphed

subluxation/luxation

Deformerende forandringer

formændring af caput femoris

acetabulum

Sekundære forandringer

periartikulære nydannelser

# Røntgenanatomi

h = caput femoris

i = collum femoris

j = fovea capitis

k = trochanter major

l = vækstzone

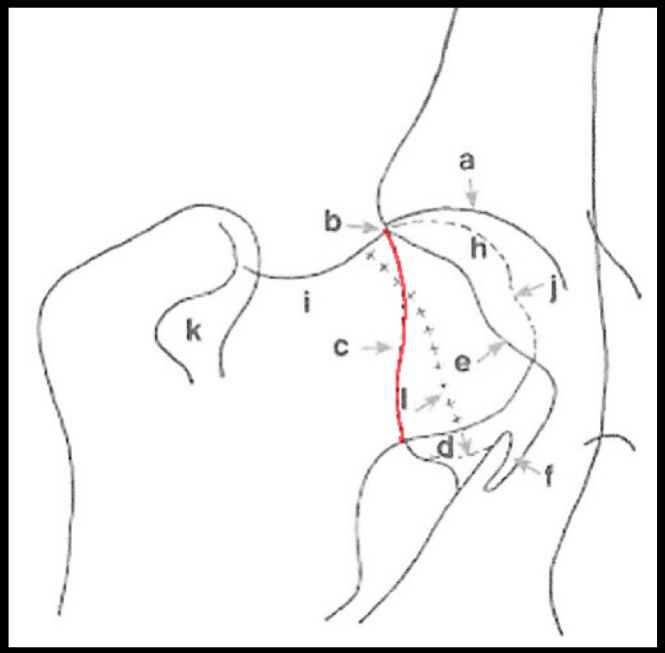


a = kraniale acetabularrand

b = kranio/laterale acetabularkant

c = dorsale acetabularrand

d = kaudale acetabularrand

e = ventrale acetabularrand

f = acetabular notch

# Laxity measurement methods

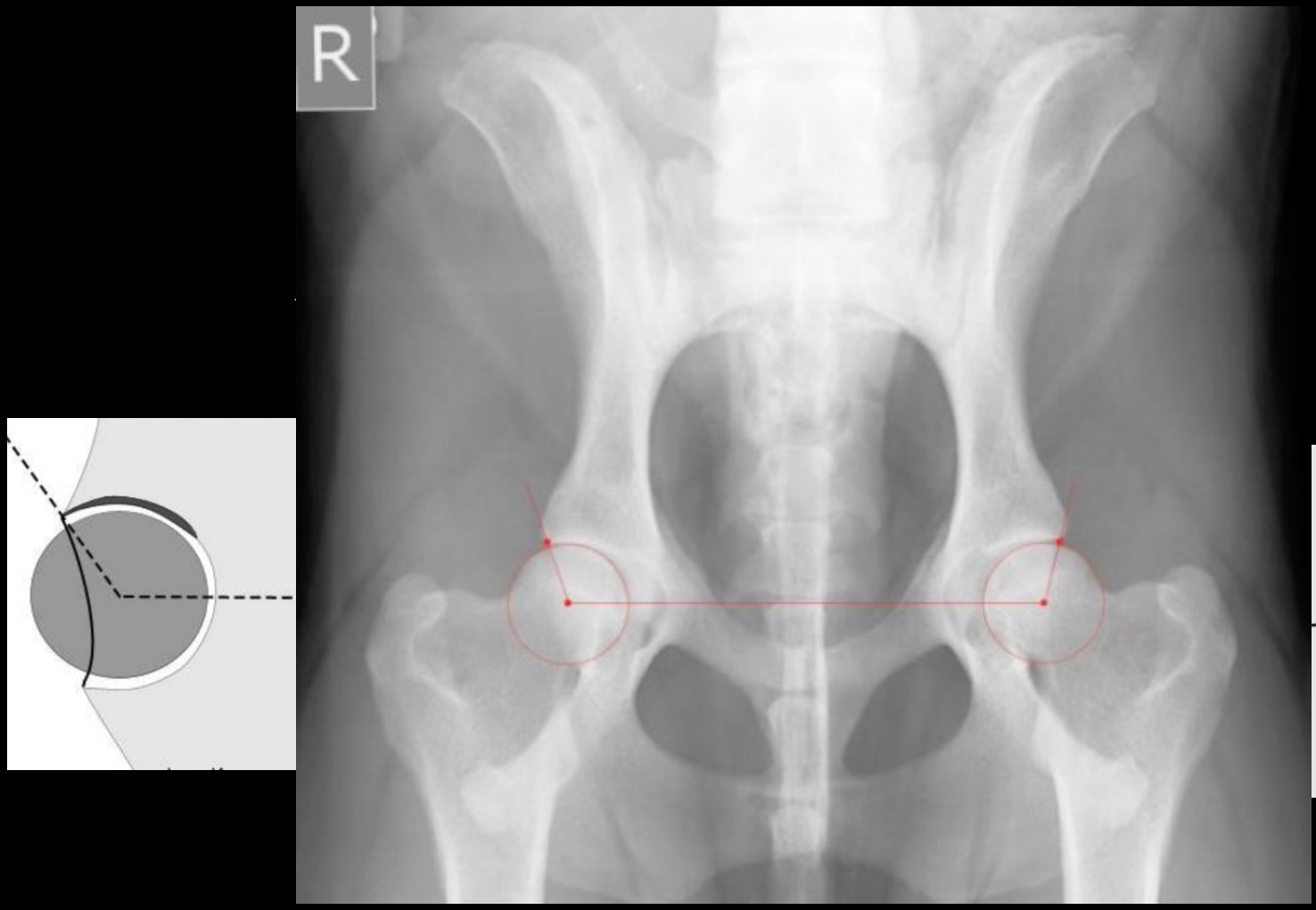


Norberg angle

>105 gr

## Percent of femoral head coverage

Centrum af caput ligger lateralt for den dorsale acetabularrand

Centrum af caput ligger medialt for den dorsale acetabularrand

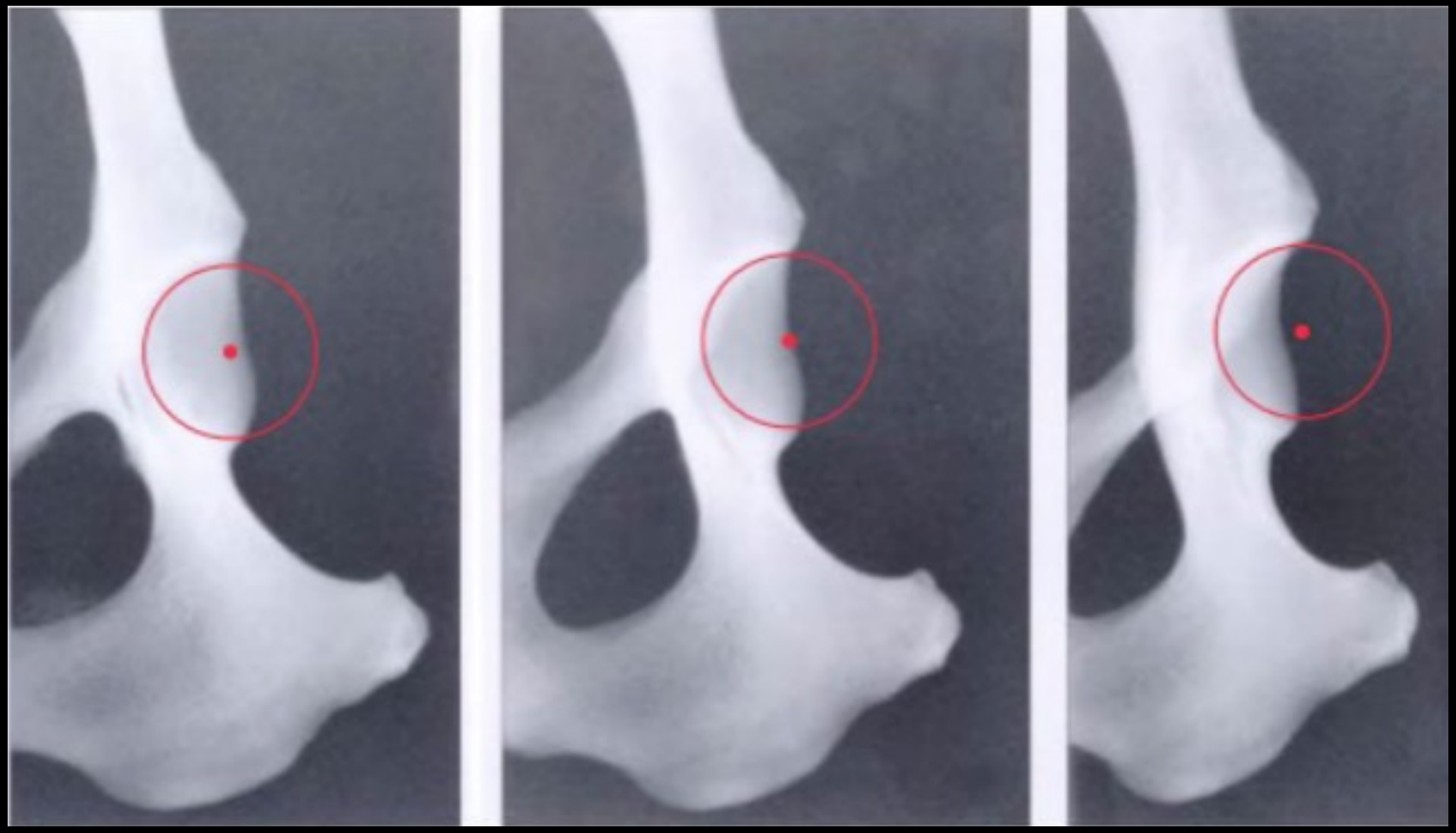

## GRADE A

**Dortmund 1991**

The femoral head and the acetabulum are **congruent**.
The **joint space** is narrow and even.
The **craniolateral rim** appears sharp and slightly rounded.
In excellent hip joints the **craniolateral rim** encircles the femoral head somewhat more in laterocaudal direction.
The acetabular angle according to **Norberg** (adapted for Pos. I) is about 105° (as a reference).

**Copenhagen 2022**

The femoral head is well centred in the acetabulum and the **joint space** is narrow and even. The subchondral bone of the femoral head and the **cranial acetabular margin** are parallel or almost parallel, with the exception of the fovea capitis.

The subchondral bone plate of the **cranial acetabular margin** is a fine line of even thickness; in excellent hip joints the subchondral bone can end before the **craniolateral rim**.

The **craniolateral rim** should be well defined and rounded, parallel to the femoral head; in excellent hips the **craniolateral rim** encircles the femoral head in caudolateral direction.

The **centre of the femoral head** is medial to the dorsal margin of the acetabulum.

The **Norberg angle** is about 105° (as a reference).

No signs of **osteoarthritic** changes are present.

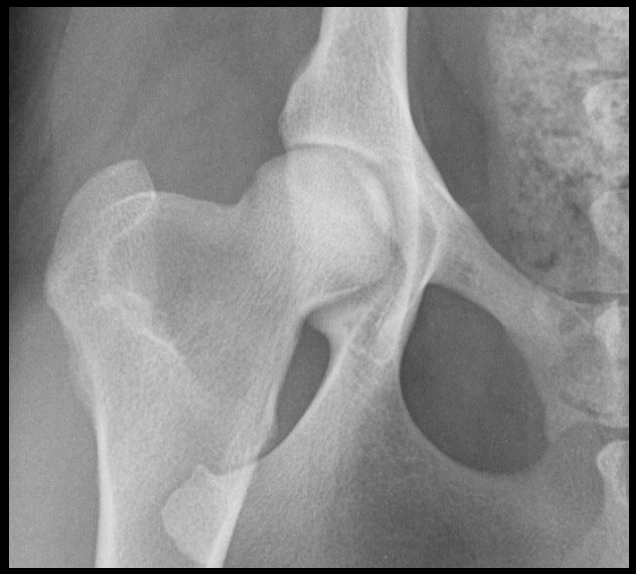

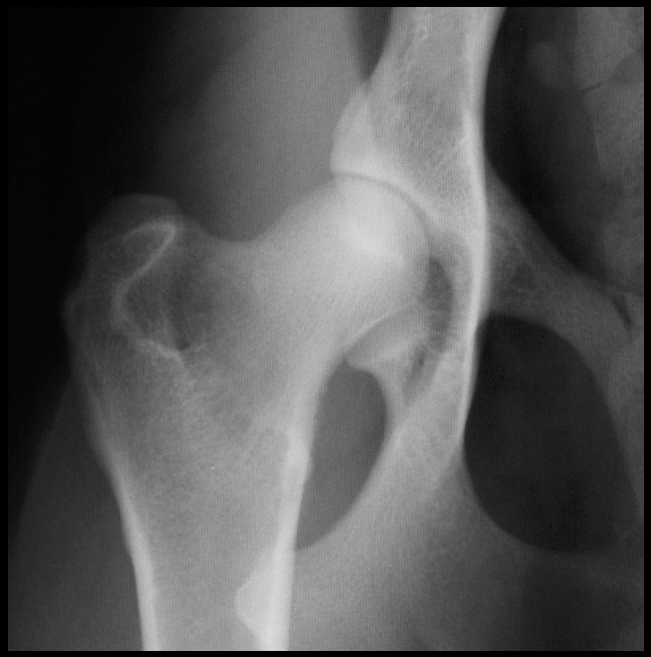

# Grade A

The femoral head is well centred in the acetabulum and the *joint space* is narrow and even. The subchondral bone of *the femoral head* and the *cranial acetabular margin* are parallel or almost parallel, with the exception of the fovea capitis

The subchondral bone plate of the *cranial acetabular margin* is a fine line of even thickness; in excellent hip joints the subchondral bone can end before the *craniolateral rim*

The *craniolateral rim* should be well defined and rounded, parallel to the femoral head; in excellent hips the *craniolateral rim* encircles the femoral head in caudolateral direction

The *centre of the femoral head* is medial to the dorsal margin of the acetabulum

The *Norberg angle* is about 105° (as a reference)

No signs of *osteoarthritic* changes are present

# Grade B

The femoral head is centred in the acetabulum and the *joint space* is narrow, however the subchondral bone of *the femoral head* and *the cranial acetabular margin* can be diverging i.e., not parallel

The subchondral bone plate of the *cranial acetabular margin* is a fine line with even thickness

At the lateral part, the *craniolateral rim* is horizontal, i.e., after its maximum in a straight line in the transverse plane

The *centre of the femoral head* is medial or superimposed to the dorsal margin of the acetabulum

The *Norberg angle* is as least 100˚ (as a reference)

No signs of *osteoarthritic* changes are present

# Grade C

The *femoral head* is not centred well in the acetabulum and the subchondral bone of the *femoral head* and *cranial acetabular margin* are diverging i.e., not parallel

The subchondral bone plate of the *cranial acetabular margin* can be slightly thickened laterally and/or slightly reduced medially

The *craniolateral rim* can be slightly flattened, i.e., the craniolateral margin diverges from the femoral head in a craniolateral direction

The *centre of the femoral head* is superimposed or lateral to the dorsal margin of the acetabulum

*Subluxation* of the femoral head, lateral or caudal, can be present

The *Norberg angle* is about 100° (as a reference)

Signs of *osteoarthritic* changes can be present

# Grade D

The *femoral head* is not centred well in the acetabulum and the subchondral bone of the *femoral head* and the *cranial acetabular margin* are obviously diverging

The subchondral bone plate of the *cranial acetabular margin* is moderately thickened laterally and/or moderately reduced medially

The *craniolateral rim* is markedly flattened i.e., the craniolateral margin leaves the femoral head in a craniolateral direction

The *centre of the femoral head* is lateral to the dorsal margin of the acetabulum

*Subluxation* of the femoral head, lateral or caudal, can be present

The *Norberg angle* is more than 90° (as a reference)

Signs of osteoarthritic changes can be present.

# Grade E

Marked dysplastic changes of the hip joint. Remodelling and deformation of the acetabulum and/or the femoral head may be present

The subchondral bone of the *femoral head* and the subchondral bone plate of the *cranial acetabular margin* are obviously diverging with obvious flattening

The *cranial acetabular margin* is markedly thickened laterally blending with the *craniolateral rim*. Thickening of the cranial acetabular margin can be absent in luxated hip joints

The *craniolateral rim* is markedly flattened i.e., the craniolateral margin leaves the femoral head in a craniolateral direction. The craniolateral rim may be absent

The *centre of the femoral head* is lateral to the dorsal margin of the acetabulum.

*Luxation* or *subluxation* of the femoral head

The *Norberg angle* is less than 90° (as a reference)

Signs of *osteoarthritic* changes can be present

# Grade E

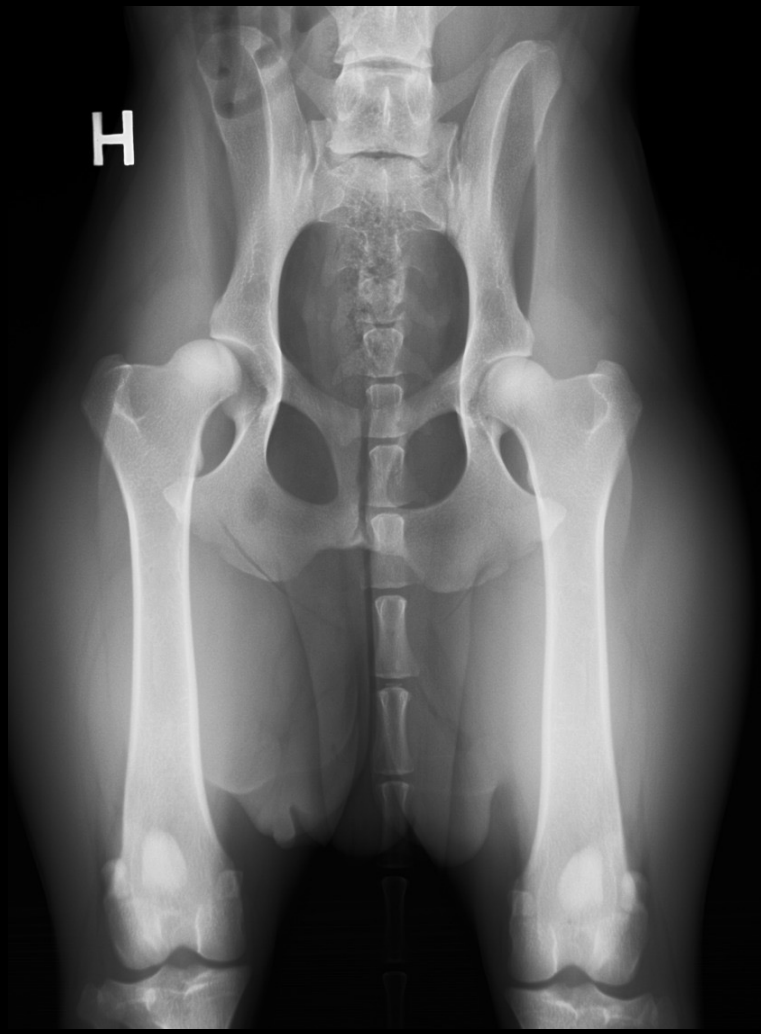
H

# HD-symptomkomplekset

Arvelig HD
- Multifaktoriel
- Polygenetisk

Erhvervet ”HD” (falsk HD-positive)
- Traume, malformation af columna og pelvis, osteoartrose

# HD?

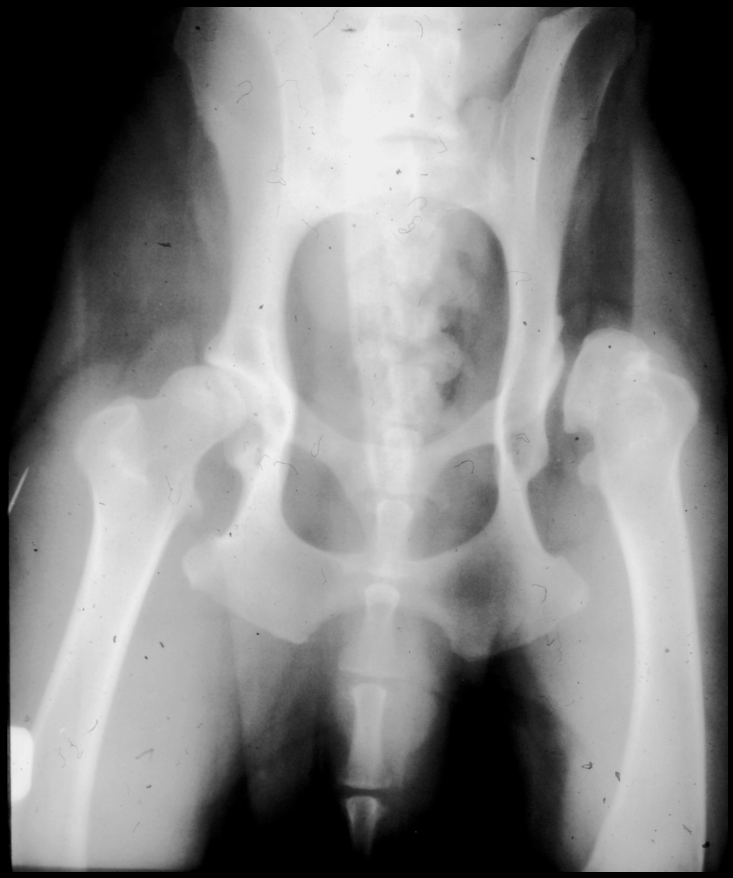

En røntgenundersøgelse kan aldrig blive en eksakt metode til at fastslå en hunds HD-status

Der foreligger ingen objektiv radiologisk undersøgelsesmetode til vurdering af HD hos hund

# Screeningsprogrammer

## Hip-extended

BVA/KC (1965)
- British Veterinary Association/Kennel Club

OFA (1966)
- Orthopedic Foundation for Animals

FCI (1974)
- Féderation Cynologique International

## Dynamisk, stress

PennHIP® (1993)
- Penn = Pennsylvania
- H = Hip
- I = Improvement
- P = Program